

Parotid Gland Abscess: A Series of Three Cases

**Ali Mohammed Makrami 1*, Shihab Abdelmunim Osman Ahmed 2*,
Amal M. Bajonaid 3*, Asma Ali Hezam 4 *, Aiman Abdullateef Ahmad 5***

1*consultant oral and Maxillofacial surgeon , Prince Mohammad Bin Nasser Hospital ,Jazan , KSA

2* specialist oral and Maxillofacial surgeon, Abu Arish General Hospital, Jazan , KSA .

3* Oral Medicine demonstrator, Faculty of Dentistry Jazan University, KSA .

4* Resident oral and maxillofacial surgery, Prince Mohammed Bin Nasser Hospital ,Jazan , KSA .

5* Resident oral and maxillofacial surgery , Abu Arish General Hospital ,Jazan , KSA .

Introduction:

Suppurative or secondary parotitis is an acute inflammatory infection of the parotid gland. It is also referred to as ascending parotitis because the pathogenesis is suggested to be an ascending bacterial infection through Stensen's duct.^(1,2) It differs from mumps in several aspects: 1- It is not contagious; 2- It frequently suppurates, and give rise to parotid abscess.⁽¹⁾

Symptoms of parotid gland abscess include: swelling at the angle of the mandible which is usually accompanied by erythema of the overlying skin, trismus, shooting pain at the area of the parotid gland, fever, lethargy, and occasional dysphagia.⁽¹⁾ The most common pathogen associated with acute bacterial parotitis is *Staphylococcus aureus*.⁽³⁾ Some predisposing conditions and factors include: dehydration, malnutrition, poor oral hygiene, xerostomia, ductal obstruction, and some chronic diseases such as diabetes mellitus.⁽⁴⁾ Among the various imaging techniques ultrasonography is considered the first line for the evaluation of parotid abscess.⁽²⁾ If left untreated it might be complicated by deep neck space infection and sepsis.⁽⁵⁾ Management includes hydration and administration of parenteral antimicrobial agent.⁽⁶⁾ In case of abscess formation, surgical drainage is required.⁽⁶⁾

Keywords Sialadenitis , Parotitis, Abscess, parotid gland

Case Reports

Case 1

An 80-year- old male patient reported to the Department of Oral and Maxillofacial Surgery, complaining from swelling in the left side of the neck and difficulty in mouth opening since 2 weeks. The history of presenting illness revealed pulsating moderate pain in the left side of the face in the parotid gland region, which suddenly started and quickly progressed, the pain was continuous, aggravated during eating and opening the mouth or touching the area. His past medical history indicated that he has hypertension. The patient was brought in a wheelchair. On physical examination ,he looked malnourished, he was lethargic and responded to painful stimuli. Vital signs and parameters were all within normal range except blood pressure, which was decreased. On extra oral examination facial asymmetry was detected. The swelling was diffused, mildly fluctuant and tender to palpation. His mouth opening was

reduced to 30 mm. The regional lymph nodes were palpable and tender. On intraoral examination, his lips were dry, he had very poor oral hygiene. Gentle milking of the left Stensen's duct revealed purulent discharge. A panoramic radiograph was unremarkable. Chest CT scan revealed very minimal degree of left pleural effusion. A diagnosis of parotid gland abscess was made based on the history and clinical findings. CBC revealed that the red blood cells and hemoglobin were below the lower normal limit, while the white blood cells were much higher the normal limit. The patient was admitted to the general ward to stabilize his condition. Medical consultations were made regarding his hypertension and blood disparities. Parenteral Amoxicillin with clavulanic acid was administered. After three days the patient's general condition was stable, the swelling became more localized, so incision and drainage was done under local anesthesia. The patient was kept under medical supervision for 10 days during which the swelling subsided and his general condition improved remarkably.

Case 2

A 74-year-old male patient referred from emergency room to the outpatient department of Oral and Maxillofacial Surgery complaining from painful swelling in the left side of the face since one month. The history of presenting illness revealed moderate pain in the left pre-auricular area, which suddenly started and progressed over one month, the pain is continuous and aggravated by opening the mouth. He is a known case of diabetes mellitus, hypertension, and chronic renal failure. On clinical examination, the patient was fully conscious and oriented to time and place, his vital signs and parameters were within normal range. On extra oral examination, facial asymmetry was evident, the swelling situated on the left side of the face under the left ear which was slightly firm and tender to palpation, his mouth opening was reduced to 32 mm. On intraoral examination, the patient showed fair oral hygiene the soft tissue showed no visible abnormality, as well as the hard tissue. Attempt to milk the left parotid gland produced no purulent discharge with moderate pain and discomfort. Ultrasonography requested to confirm the diagnosis. The ultrasonography report revealed hypo-anechoic lesion, with irregular margins. Which is a characteristic sign of evolution of parotid gland inflammation into an abscess on ultrasound. Based on the clinical presentation and history combined with ultrasound report a diagnosis of parotid gland abscess was made. Medical consultations regarding the blood glucose level and hypertension and renal functions were made. The patient was admitted to general ward to monitor and stabilize his general condition. Parenteral Amoxicillin with clavulanic acid and metronidazole were given. After three days the swelling increased slightly but then started to gradually decrease in size. After 7 days the swelling remarkably subsided. Milking of the left parotid gland and aspiration produced no purulent discharge. The presenting symptoms subsided by day 10 and the mouth opening was restored to normal range.

Case 3

A 75- year- old Saudi female presented to the department of oral and maxillofacial surgery at Abu Arish General hospital with a complaint of swelling in the right side of face since 3 weeks, as seen on figure 1. The history of presenting illness revealed moderate pain in the right pre-auricular area, which was sudden in onset, continuous in nature, aggravated by eating and opening the mouth. The past medical history revealed blindness in eyes, cerebrovascular accident (CVA),hypertension (HTN), and congestive heart failure (CHF). The patient was brought in a wheelchair. On physical examination, she looked malnourished and responded to painful stimuli. All vital signs were within normal range.On extra oral examination, facial asymmetry was obvious,with swelling of soft tissues over the right pre-auricular area,the tissue was slightly indurated and exquisitely tender to palpation,her mouth opening was reduced to 29 mm. The regional lymph nodes were palpable and tender. On intra oral examination, the patient had very poor oral hygiene and multiple grossly carious teeth, the dorsal surface of the tongue was dry and fissured. Gentle milking of the right Stensen's duct produced purulent discharge. A diagnosis of parotid gland abscess was made based on history and clinical findings. Medical Consultation was coordinated as necessary. The patient was admitted to monitor her general condition. Parental Amoxicillin with clavulanic acid was given. After 3 days the swelling became more localized.The patient was kept under medical supervision for seven days. The presenting symptoms subsided by day 7 without need for incision and drainage, and the patient was discharged in overall good condition. Figure 2 shows the area after healing.

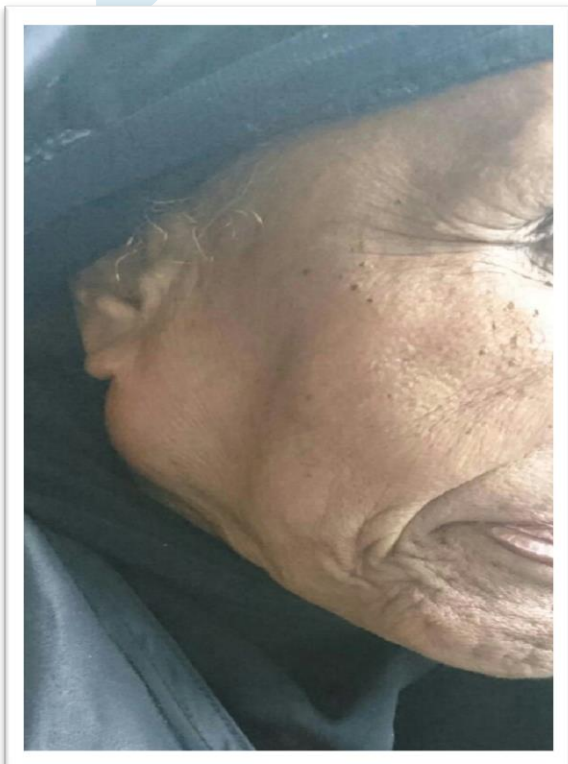


Figure 1: the swelling in the right pre-auricular area.

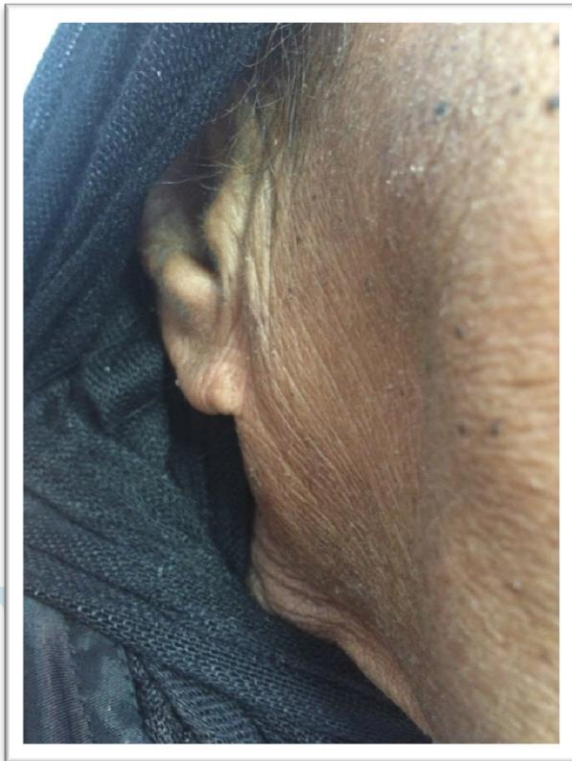


Figure 2: remarkable improvement after one week of antimicrobial therapy.

Discussion

The etiology of bacterial parotitis is assumed to be ascending infection from the oral cavity. Many etiologic factors have been linked with acute suppurative parotitis with dehydration being the most significant⁽⁷⁾ Despite its rarity, neglected elderly patients with systemic diseases such as hypertension, diabetes mellitus, immunosuppression, or dental infections, are prone to develop ascending parotitis. Early recognition and immediate intervention could spare the patient more serious consequences such as deep neck space infection. Ultrasonography offers an accurate and easy way to support clinical diagnosis of parotid gland abscess, especially for patient with impaired renal function who are unable to tolerate the contrast agent for CT scan. Hydration and antimicrobial therapy are essential in the management of ascending parotitis. The presence of purulent discharge mandates incision for drainage.

References:

1. Bucknall R. The Pathology and Prevention of Secondary Parotitis. *Medico-surgical transactions*. 1905;88:1-33.
2. Viselner G, van der Byl G, Maira A, Merico V, Draghi F. J Ultrasound. 2013 Mar 2;16(1):11-5. doi: 10.1007/s40477-013-0006-0. eCollection 2013.
3. Nusem-Horowitz S, Wolf M, Coret A, Kronenberg J. Acute suppurative parotitis a parotid abscess in children. *Int J Pediatr Otorhinolaryngol*. 1995;32:123–127. doi: 10.1016/0165-5876(94)01120-M.
4. Tan VE, Goh BS. Parotid abscess: a five-year review—clinical presentation, diagnosis and management. *J Laryngol Otol*. 2007;121:872–879. doi: 10.1017/S0022215106004166.
5. Chi TH, Yuan CH, Chen HS. Parotid abscess: a retrospective study of 14 cases at a regional hospital in Taiwan. *B-ENT*. 2014;10(4):315-8. PubMed PMID: 25654957.
6. Brook I. Acute bacterial suppurative parotitis: microbiology and management. *J Craniofac Surg*. 2003 Jan;14(1):37-40. PubMed PMID: 12544218.
7. Fattahi TT, Lyu PE, Van Sickels JE. Management of acute suppurative parotitis. *J Oral Maxillofac Surg*. 2002 Apr;60(4):446-8. Review. PubMed PMID: 11928106.

