

CERVICOFACIAL CELLULITIS MANAGEMENT: A Review of 136 Cases

ZAHRA SAYAD¹, NAJWA BELHAJ², Pr. S. NITASSI², Pr. R. BENCHEIKH², Pr. A. OUJILAL², Pr. M.A. BENBOUZID², Pr. S. BENAZZOU¹, Pr. L. ESSAKALLP², Pr. M. BOULAADAS¹

¹ Service de Chirurgie Maxillo-Faciale et stomatologie centre hospitalier universitaire Rabat

² Service ORL-CCF centre hospitalier universitaire Rabat

Summary:

Our work aims to study the epidemiology and paraclinical profile of our patients, to evaluate their therapeutic management and their evolution. We included 136 patients treated between January 2018 and January 2020. Our series regains a male predominance of 72.6%. Dental origin is the most common etiology. CT scans with contrast product injection are the key examination of the initial balance sheet. Antibiotic therapy and surgery have allowed a good evolution. Cervicofacial cellulitis is a potentially serious condition, often affecting young adults whose hospital mortality must be reduced if it is diagnosed early and given immediate medical-surgical management.

Key Words: Cervicofacial, Infection, management, prognosis.

Introduction:

Cervicofacial cellulitis is refers to a rapidly progressing infection of the fascial spaces of the head and neck. These are serious conditions that have an extensive rapid tendency and can put life-threatening. The development of antibiotics has made it possible to radically change the evolution of these cellulitis.

Purpose of work:

The purpose of this study was to study the epidemiological-clinical and paraclinical profile of our patients, to evaluate their therapeutic management and their evolution.

Materials and methods:

This is a retrospective study carried out in the service of maxillo-facial and ENT emergencies at CHU Rabat about 136 cases of cervicofacial cellulitis collected between January 2018 and January 2020. The files studied involved patients treated in an intra-hospital setting. the data reception was via operating sheets and the statistical study is carried out by the software SPSS 20 .0. The analysis of the data was done with the same software: Quantitative variables were expressed on average \pm standard deviation and qualitative variables as a percentage.

Results:

Our series included 96 cases with a clear male predominance 72.6%. The average age of our patients was 30 years most of our patients was in the age range between 20-30 years, for the history of patients in our series we found 30 years; 48% of patients have used a no-steroidal ant inflammatory intake,31% had a history of diabetes,12% taking corticoids;9% taking immunosuppressants and 4% had an immunosuppression field. (figure1.2)

Etiology is dental in 52% of cases, pharyngeal in 25% of cases,3% of neoplastic origin and in 20% the origin was indeterminate.

CT with contrast product injection was requested in all our patients, the collection interested deep spaces in 34% of cases. For complications of cellulite were in 46% sepsis, then in 9% thrombophlebitis, in 6% understanding of VADS and in 3% of mediastinitis in our series 0 cases of decline. (figure3.4.5)

All patients received parenteral antibiotic therapy. Eleven patients were put on corticosteroids: parenteral. 120mg twice a day. The main analgesic molecule used was paracetamol. We performed surgical drainage in 126 patients that consisted of an incision with the bistoury evacuation of the excision pus of the necrotized tissues and abundant washing with betadine and oxygenated water with Delbet drain in 6% of patients. After evacuation of the pus, surgical drainages and repeated washings were carried out. Ten patients did not require surgical treatment.

Discussion:

The origin of cervicofacial cellulitis is most often dental, tonsil or other (skin, sinus...). Our results are consistent with these findings. The high incidence of odontogenic cellulitis is mainly due to poor oral hygiene [1]. The factors favoring cervicofacial cellulitis are numerous: diabetes, alcohol-smoking poisoning, immunodepression, taking nonsteroidal anti-inflammatory drugs [2.3]. In our series, tobacco is the second most important risk factor after diabetes.

The diagnosis of cervicofacial cellulitis is clinical based on the conjunction of a severe infectious condition and cervicofacial physical signs. Cervicofacial swelling, almost constant, is inflammatory and painful. She is alone, she is very evocative of cellulite. The association with trismus and odynophagia is usual. Dyspnea should have an over-added mediastinitis sought. General signs are rarely lacking fever, chills, sweating [2.4].

The germs involved vary; they are most often saprophyte germs of the oral cavity.

A dental panoramic x-ray is required in case of odontogenic cellulitis. It can objectify decayed outbreaks, peri-apical osteolysis zones and granulomatous outbreaks. The chest x-ray diagnoses complications in particular the spread of the infection to the mediastina. The CT scan, thanks to its excellent resolution in tissue and bone density, helps to clarify the inflammatory nature of cervical swelling, to evaluate its extension and to search for a collection whose highlighting would require surgical drainage. CT scans are of considerable input in the diagnosis of a mediastinal extension whose initial signs are sometimes extremely frustrated [5-6].

Thrombophlebitis and hemorrhage can be a problem for the development of cervicofacial cellulitis [7.8]. The mediastina-pleuro-pericardial extension of the infection is of bad prognosis and is frequently associated with severe septic condition and multivisceral failure [9]. In our series, mediastinal extension is found in 3% of patients.

Medical treatment is based on targeted and effective antibiotic therapy for severe forms as part of appropriate resuscitation. Therapeutic protocols vary in the literature. For the most part, the reference association is art: β -lactam antibiotics (penicillin G at the dose of 6 to 20M IU/24h intravenous), aminoglycoside antibiotics that have an effective synergistic effect on the staphylococcus and on some gram-negative bacillus (Gentamycin at 160mg/24h) and Metronidazole is known to be active on anaerobic at the 1.5g/24-hour dose. The dose and duration of treatment depend on the type and evolution of cellulite [10]. Surgical treatment is necessary in cases of purulent collections or necrotic ranges. The intervention must be as complete as possible and the path first wide and expandable; it is a matter of draining but also of excising necrosis and flattening all cellulitis zones [11]. In the case of associated mediastinitis, thoracotomy drainage during the same operating time will be considered. Tracheotomy is required in retro-pharyngeal cellulitis because of the risk of rupture of these abscesses during intubation maneuvers [12].

Hyperbaric oxygen therapy allows a bacteriostatic effect on anaerobic germs but is not commonly used. Stomatological treatment is most often performed after cooling the infectious process. The best treatment remains preventive: antibiotic prophylaxis during dental care, oral hygiene, avoidance of the abusive prescription of anti-inflammatory.

The various published series have a mortality rate in the range of 20-40% [13-14]. In our series mortality is zero.

Conclusion:

Cervicofacial cellulitis complicates a dental or oropharyngeal infection. The severity of this condition requires a balance of the extent of the lesions thanks to the CT scan, the realization of which should not delay the start of the medical-surgical treatment. Hospital mortality from cervical cellulite should be reduced if diagnosed early and given immediate medical management.

Conflict of interest:

The authors declare no conflict of interest.

References:

- 1-Boca P, Moreau P. Complications cervicales d'infections dentaires: les causes- le diagnostic- le traitement. Acta OtoRhino-laryngol. 1995 ; 49: 37-44.
- 2- Benzarti S, Mardassi A, Ben Mhamed R et al. Les cellulites cervico-faciales d'origine dentaire à propos de 150 cas. J Tun ORL. décembre 2007; 19.
- 3- Kpemissi E. Cellulites cervico-faciales d'origine bucco-dentaire: Etude de 26 cas au CHU de Lomé. Rev Laryngol Oto-Rhinol. 1995 ; 116: 195-7.
- 4- Mathiau D, Neiviere R, et al. Cervical necrotizing fasciitis: clinical manifestations and management.
- 5-Mateo J, Petipas F, Payen D. Dermohypodermes bactériennes nécrosantes et fasciites nécrosantes. Cellulites ORL Annales Françaises d'Anesthésie et de Réanimation. 2006;25:975-977.

- 6- Verdalle P B, Rouguet E, Raynal M et al. Les cellulites cervico-médiastinales nécrosantes: A propos de 3 cas. *OtoLaryngol Chir Cervico-Fac*. 1997 ; 114: 302-9.
- 7- Clifford-Jones R E, Ellis C J K et al. Cavernous sinus thrombosis. *J Neurol Neurosurg Psychiatry*. 1982;45: 1092- 1097.
- 8- Martyane C, Alauzen M, Alrinc P et al. Descending necrotizing mediastinitis: advantage of mediastinal drainage with thoracotomy. *J Thorac Cardio-Vasc Surg* .1994; 107: 55-61.
- 9- Zeitoun I M, Dhanarajani P J. Cervical cellulitis and mediastinitis caused by odontogenic infections: report of two cases and review of the literature. *J Oral Maxillo-Fac Surg* .1995; 53: 203- 8.
- 10- Bédos J P. Dermohypodermites bactériennes nécrosantes et fasciites nécrosantes: quels antibiotiques et comment?. *Annales Françaises d'anesthésie et de réanimation*. 2006; 25:982-985.
- 11- Lortat-Jacob A. Hypodermites et fasciites nécrosantes des membres chez l'adulte: Prise en charge chirurgicale. *Med Mal Infect*. 2000 ; 30 Suppl 5: 438-45. PubMed | Google Scholar
- 12- Reyford H, Boufflers E, Baralle MM et al. Cervico-facial cellulitis dental origin and tracheal intubation. *Ann Fr Anesth Reanim*. 1995; 14(3): 256-60. PubMed | Google Scholar.
- 13- ROMAIN, P1 ; SCHMIDT, P; HANNION, X; LE TARNEC, A; CHALUMEAU, F; LEGROS, M. Gangrenous cervico-facial odontogenic cellulitis. Report on 11 cases. *Revue de stomatologie et de chirurgie maxillo-faciale*. 1989, Vol 90, Num 6, pp 428-437.
- 14- S. Rouadi, L.Ouasssi, R.El Khiati, R.Abada, M.Mahtar, M.Roubal, Abdellah Janah1 , Mustapha Essaadi1 , Fatmi Kadiri1. Les cellulites cervicofacial à propos de 130 cas.2013

Figures:

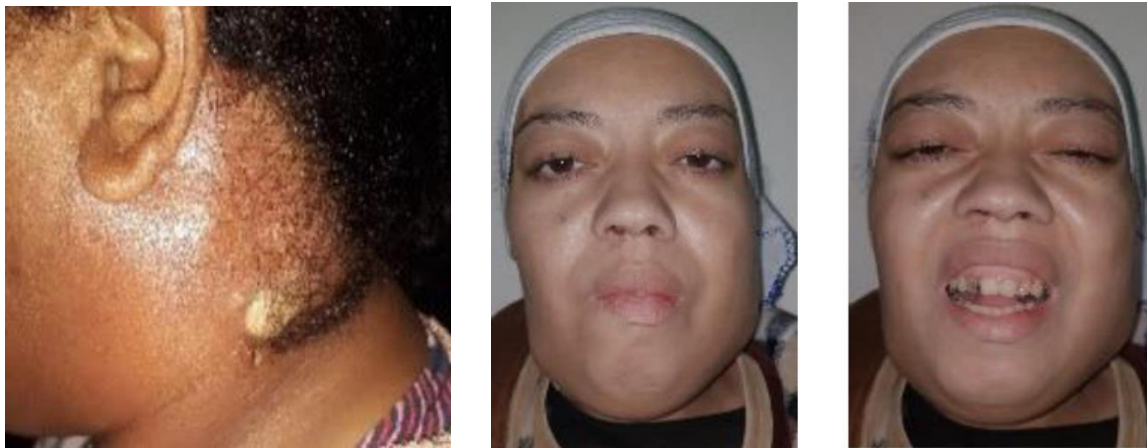


Figure 1 et 2: patient's picture with a cervicofacial cellulitis.

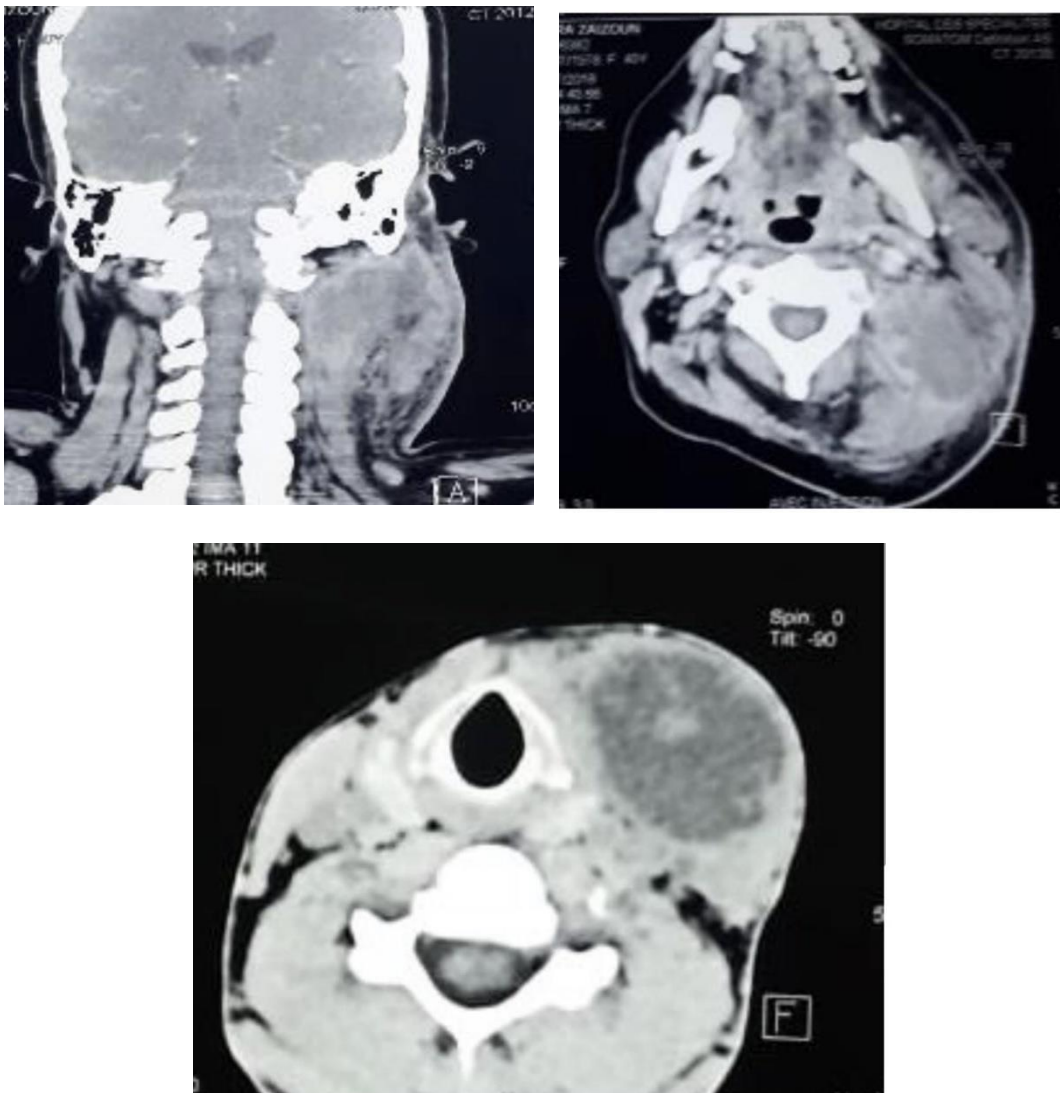


Figure 3,4 et 5: scan cuts showing the pus collection.